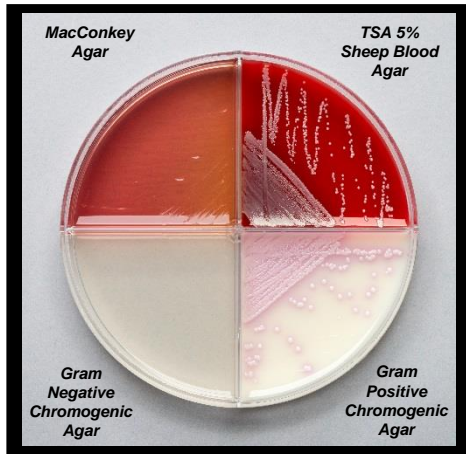
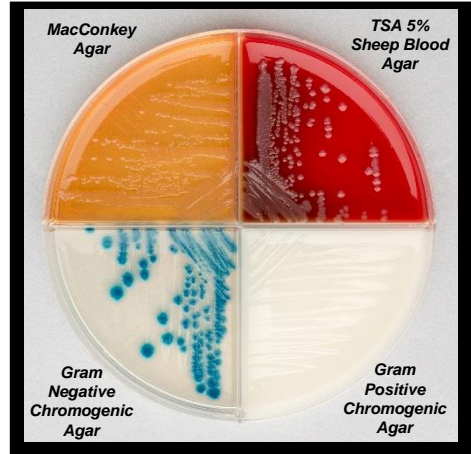


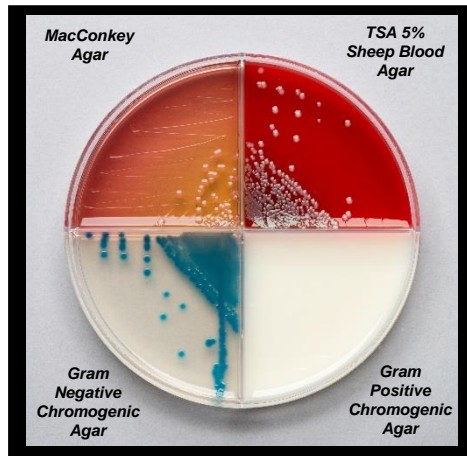
EQUINE UTERINE CULTURE: COMMON CONTAMINANTS



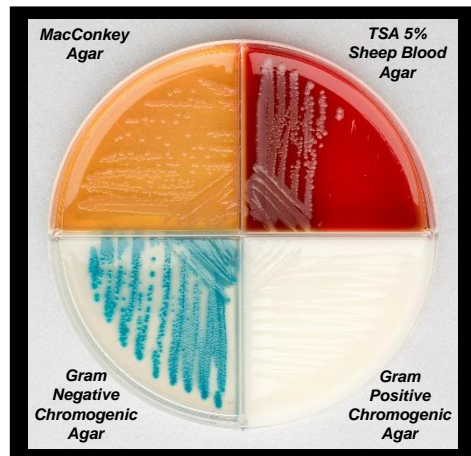
Staphylococcus aureus



Enterobacter radicincitans



Enterobacter aerogenes



Citrobacter koseri

Organism	Gram Stain	Morphology	TSA – 5% Sheep Blood Agar	MacConkey Agar	Chromogenic Agar	Comments
<i>Staphylococcus aureus</i>	Positive	Cocci (clusters)	Pinpoint grey colonies	No growth	Circular light pink or white colonies	
<i>Enterobacter radicincitans</i>	Negative	Rods	Grey mucoid colonies	Light pink or clear mucoid colonies	Circular or irregular, rough, dark blue colonies [+/- slight pink halo]	Negative Urease Test
<i>Enterobacter aerogenes</i>	Negative	Rods	Grey mucoid colonies	Pink mucoid colonies	Circular, mucoid blue colonies [+/- slight pink halo]	Negative Urease Test
<i>Citrobacter koseri</i>	Negative	Rods	Pinpoint, grey, mucoid colonies	Light pink or clear mucoid colonies	Light blue or teal colonies	Negative Urease Test, Aromatic

